

**CASE REPORT****WHY EARLY DIAGNOSIS IS THE ONLY HOPE IN OVERLAP SYNDROME**Disha Varu<sup>\*1</sup>, Dr Darshan Raval<sup>1</sup><sup>1</sup>Medicine department at SSG hospital Medical College Baroda**Corresponding Author:** Disha varu, Medicine department at SSG hospital Medical College Baroda**Email:** dvaru18@gmail.com**ABSTRACT**

Overlap syndrome is a rare entity which is used to describe a condition when two or more autoimmune diseases occur in a same patient . Due to the ill-defined progression of the disease and the symptoms which are not true to one disease, it is usually missed. The aim of this clinical case report is to highlight this unusual disease to avoid incorrect diagnosis. A 26 year old female presented to the hospital with symptoms of joint stiffness. She demonstrated symptoms including almost all the organ systems of her body, pointing towards the possibility of an autoimmune disease. She had physical deformities characteristic of rheumatoid arthritis; parotid swelling and inability to open mouth commonly found in sjogren syndrome; and cardiomegaly along with pulmonary hypertension indicative of systemic sclerosis. Various laboratory tests and ultrasound were also done in this patient. However, the confirmation of presence of more than one autoimmune disease in this patient was given by serological reports . At last ,a clinical diagnosis of overlap syndrome was made. Treatment in such patients is in accordance to the presenting symptoms, but as in this patient the risk vs the benefit ratio was very high, therefore our treatment was limited only to the conservative part. Hence, tendonoplasty and physiotherapy was done. Unfortunately she died in ICU due to right ventricular failure. We conclude that in diseases like overlap syndrome which are at first hard to diagnose and if diagnosed impossible to reverse ,early presentation and early treatment is the only hope.

**KEYWORDS:** Autoimmune, Antibodies, Systemic sclerosis, Overlap disease.**INTRODUCTION**

In Rheumatology, when two or more autoimmune disorders of connective tissue are confirmed in a single patient the term Overlap syndrome is often used. It usually includes diseases like

Mixed connective tissue disorder [1]

- Rheumatoid arthritis
- scleroderma (systemic sclerosis)
- systemic lupus erythematosus
- polymyositis
- Sjogren's syndrome
- Dermatomyositis
- Eosinophilic granulomatosis with polyangiitis(EGPA)
- Autoimmune thyroiditis
- Antiphospholipid antibody syndrome

These diseases in terms of individual presentation have nothing or little in common but share a common denominator of autoimmunity (where the body's immune system attacks its cells or self-antigen). This common association can help in the treatment of such patients. The disease states in overlap syndrome can occur successively with one disease symptoms following the other over years or the symptoms may overlap differing entirely from classic disease. As many as 25% of rheumatic disease patients with systemic symptoms aren't diagnosed till date, no connection between various components of overlap syndrome is present .However, it can provide several opportunities to explore the connections between autoimmune diseases.

In recent years these disease states are identified through antibody markers like:

Mixed connective tissue disease-anti-RNP

Sjogren's / myositis-anti-SSA anti-SSB

Myositis / scleroderma-anti-Ku

Scleroderma:

Polymyositis and pulmonary fibrosis:anti-Jo-1

A reason for dividing cases in such a manner is to seek clarity for prognosis and treatment, but on a deeper level it is hoped that antibody origin and antigen association will provide us insights into the pathogenesis and aetiology [2]

Sometimes, the disease presentation is so vague that it is very difficult to make the diagnosis and thus treatment cannot be started. This delay can lead to fatal outcomes or deformities that are difficult to reverse. Although Modern rheumatology drugs provide significant improvement still complete resolution is uncertain. Like in any autoimmune overlap too early detection is the only most promising cure.

The present case is of a 26-year-old female with accidental findings related to overlapping syndrome diagnosis is made clinically and based on antibodies present.

**CASE PRESENTATION**

A 26-year-old female came to SSGH on 26/11/21 with a high-grade fever without chills and rigour for the past 2-3 days. On admission her vitals are stable. Treatment was started with fluid therapy. On physical examination, it was found that she also had joint stiffness of both upper and lower limbs. The stiffness and deformities were upto an extent that patient was unable to carry out daily activities without support.

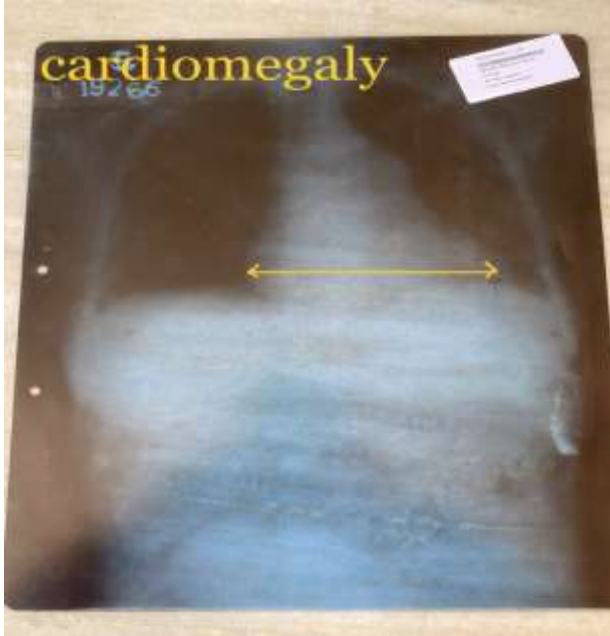History inclusive of an event 8 years ago where she experienced high fever and joint pain in all limbs for 1 week which resolved within 1 week and was followed by dull pain and stiffness. She took no medication for the above symptoms. She had multiple joint pain including the knee joint, ankle joint, elbow joint, and proximal and distal interphalangeal joint pain. The joint deformity was gradual in onset and bilaterally symmetrical starting from small joints at first followed by knee joint 2.5 years ago followed by the elbow, fingers and ankle joints 1.5years ago. She also had a history of colour changes in fingers on cold exposure. History of Breathlessness with dry cough

Without haemoptysis present. She also gave a history of dryness of mouth with dry food and dryness of eyes along with gritting sensation in the eyes for the last 15 days

Parameters	Reference value	Results
S.albumin	3.2-5gm/dl	2.90gm/dl
S.globulin	2.3-3.6gm/dl	2.70gm/dl
S.ALT(SGPT)	0-40IU/L	19.00IU/L
S.AST(SGOT)	0-37IU/L	30.00IU/L
S.alkaline phosphate (ALP)	28-111IU/L	477.00IU/L

*TABLE 1- Lab investigation was done which are according*

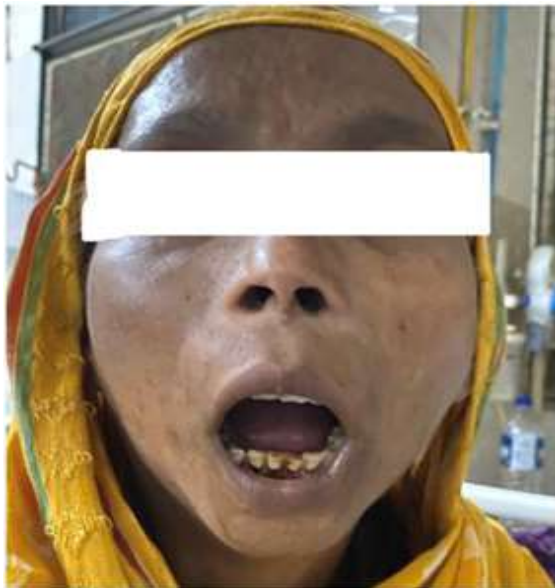On the X-ray chest, cardiomegaly (image1) was present.



**FIGURE 1-**

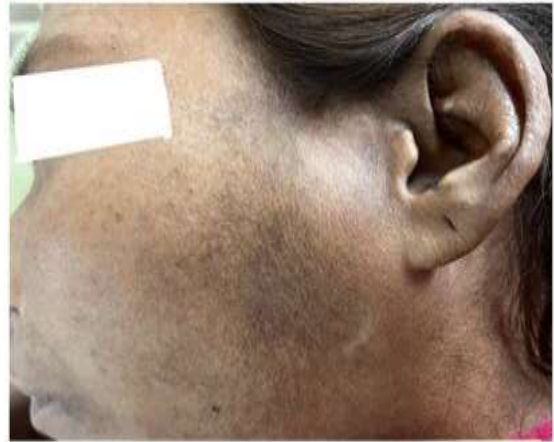On ultrasonography hepatomegaly (148mm) with mild fatty changes along with moderate to gross ascites was present.

Her vitals were stable. On physical examination, she had pallor and bilateral facial puffiness with a pinched nose (image 2) and restriction in opening her mouth. image2



**Inability to open mouth and pinched nose**

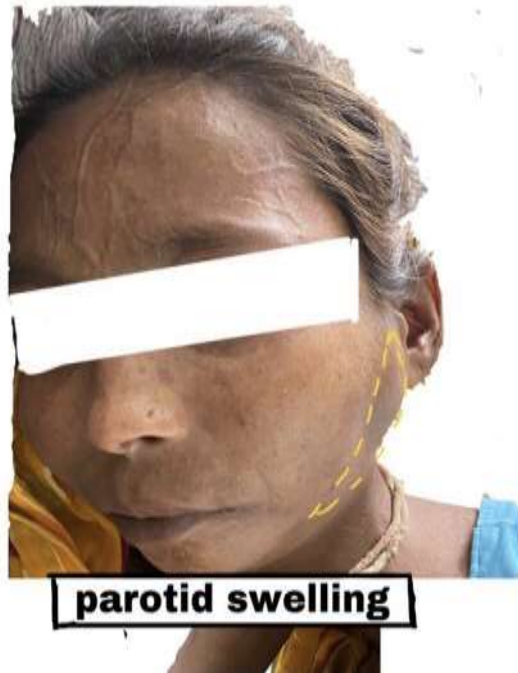**FIGURE 2-** The skin over the face and fingers was shiny and taut. Salt and pepper type skin



**salt and pepper skin**

**FIGURE 3-** Callous over elbow, knuckles and knee joint present. On examining the neck area

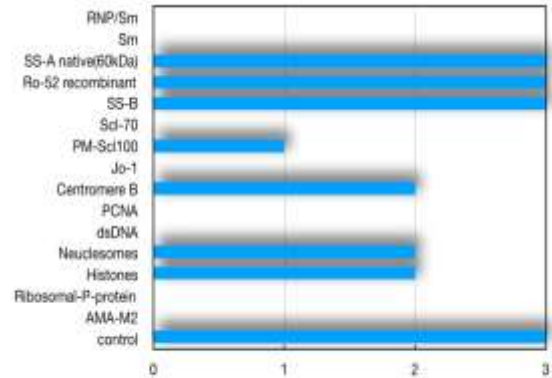
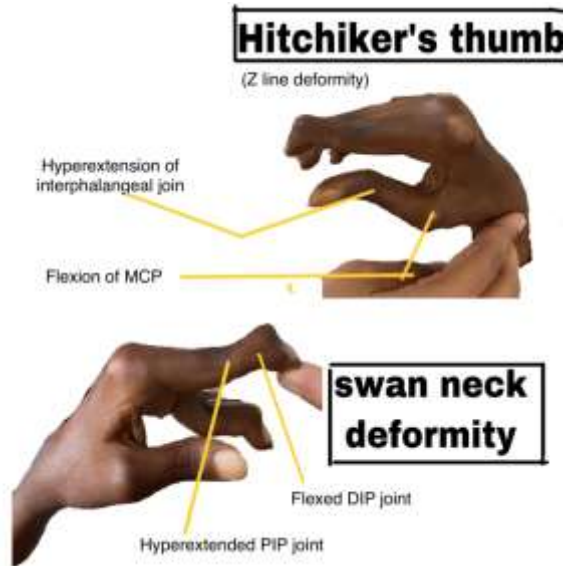Parotid swelling was visible (image 4)



**parotid swelling**

**FIGURE 4-** She had typical deformities of the hand related to rheumatoid arthritis which were:

Hitchhiker's deformity (image 5) and swan neck deformity (image 6)



On neurological examination, she had bilateral symmetrical findings as follows: (table1)

FIGURE 5- Serological findings in this patient are as follow:

<b>joints</b>	
	restricted abduction above head
	flexed with restricted movements
	ulnar deviation
<b>knee</b>	flexed with restricted movements with rheumatic nodules present

TABLE 2-

**CONCLUSION**

Overlap syndrome can present initially with inflammatory conditions( raised ESR, fever) but if the presentation is late like in this patient, that association may not be appreciated. Overlap syndrome usually occurs in the case of Rheumatic disease so whenever a patient does not fit in one of the classical diseases; extensive clinical, histological, serological investigations should be done. Usually, treatment for the patient with the overlap autoimmune disorder includes corticosteroids and immunosuppressants. The patient should be treated according to the clinical presentation:

- corticosteroids: for inflammation
- Methotrexate and anti-TNF inhibitors for arthritis

cellcept or tacrolimus for lungs

Recently for the treatment of refractory cases, biological drugs like anti-TGF alpha or anti-CD20 monoclonal antibodies are used but there are reports of such drugs triggering disease have been found[3]. DMARDs (disease-modifying anti-rheumatoid drugs) can be used in such patients. Pulmonary hypertension can be treated with appropriate drugs, late presentation may make hypertension resistant in such cases drugs like bosentan cannot be used. Early age presentation results in a more deadly outcome and worsening condition. Once deformities sets in the last resort for it is physiotherapy including various exercise and surgery like tendonoplasty, which was done in this patient. Lung transplantation was advised to the patient but she denied

it. After a few months, she was admitted to ICU with symptoms of breathlessness at rest and later died due to right ventricular failure (a complication of pulmonary hypertension).

Hence, early presentation remains the number one cure for autoimmune diseases like overlap syndrome.

1. Maddison PJ (December 1991). "Overlap syndromes and mixed connective tissue disease". *Current Opinion in Rheumatology*. 3 (6): 995–1000. doi:10.1097/00002281-199112000-00016. PMID 1772755. S2CID
2. Royal National Hospital for Rheumatic Diseases, Upper Borough Walls, Bath, UK. PMID: 1772755 DOI: 10.1097/00002281-199112000-00016
3. Iaccarino L, Gatto M, Bettio S, Caso F, Rampudda M, Zen M, Ghirardello A, Punzi L, Doria A (January 2013). "Overlap connective tissue disease syndromes". *Autoimmunity Reviews*. 12 (3): 363–73. doi:10.1016/j.autrev.2012.06.004. PMID22743033.